

Approach to Leukocoria



Developed by Chris Novak, Dr. Natashka Pollock and Dr. Mel Lewis for PedsCases.com

Hi everyone, my name is Chris Novak. I am a medical student at the University of Alberta. Today's podcast is designed to give medical students an organized approach to the physical exam finding of leukocoria, or an abnormal red reflex in children. This podcast was developed with Dr. Melanie Lewis, a general pediatrician and Professor at the University of Alberta and Dr. Natashka Pollock, a pediatric ophthalmologist at the Stollery Children's Hospital in Edmonton, Alberta.

The term leukocoria refers to a "white pupil" when examining the eye. In some cases leukocoria may be grossly apparent, or may be noticed by parents in photographs, however it is often an incidental finding on physical exam. While leukocoria is not a common finding, it is a critical sign of vision- and potentially life-threatening conditions including cataracts, hemorrhage, and malignancy like retinoblastoma. Different causes of leukocoria can present from the neonatal period and throughout childhood hence, the American Academy of Pediatrics recommends that all neonates have their red reflex examined before discharge from hospital, and subsequently at all well-child visits. Thus, it is important that all physicians looking after children recognize the critical nature of this presentation so that it is not missed. A late diagnosis may result in permanent vision loss.

Objectives

- 1) Review the anatomy of the eye
- 2) Demonstrate an approach to examining the red reflex in children using a direct ophthalmoscope
- 3) Develop a differential diagnosis for leukocoria based on anatomical structures
- 4) Discuss the initial steps of management and referral in a child with leukocoria



Developed by Chris Novak, Dr. Natasha Pollock and Dr. Mel Lewis for PedsCases.com

After listening to this podcast the learner should be able to:

Review the anatomy of the eye

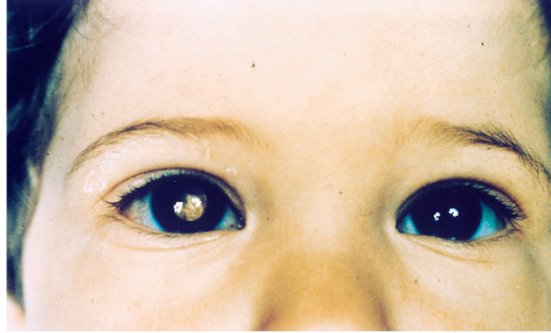
Demonstrate an approach to examining the red reflex in children using a direct ophthalmoscope

Develop a differential diagnosis for leukocoria based on anatomical structures

Discuss the initial steps of management and referral in a child with leukocoria

Case

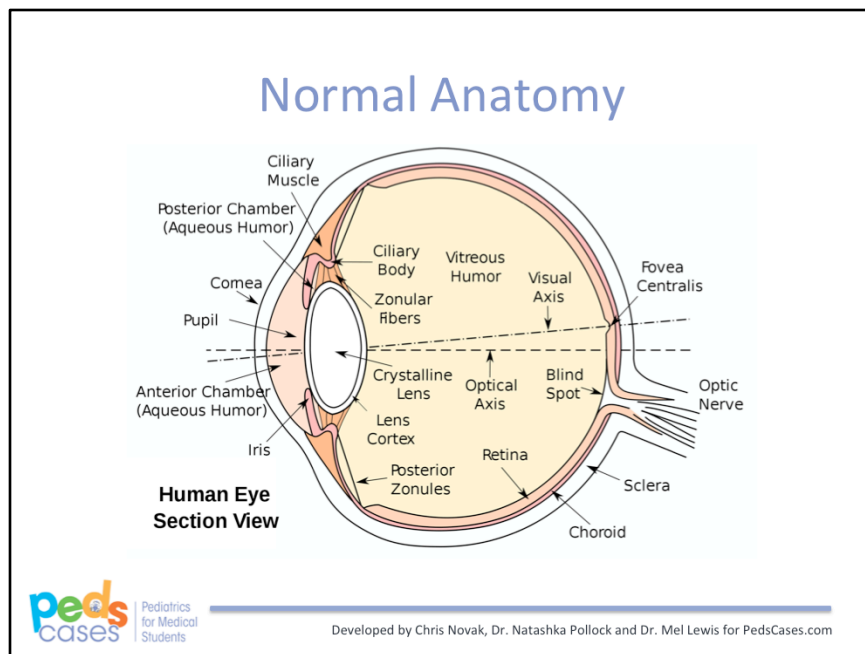
Oliver, 18-month-old male. Otherwise well.



Developed by Chris Novak, Dr. Natasha Pollock and Dr. Mel Lewis for PedsCases.com

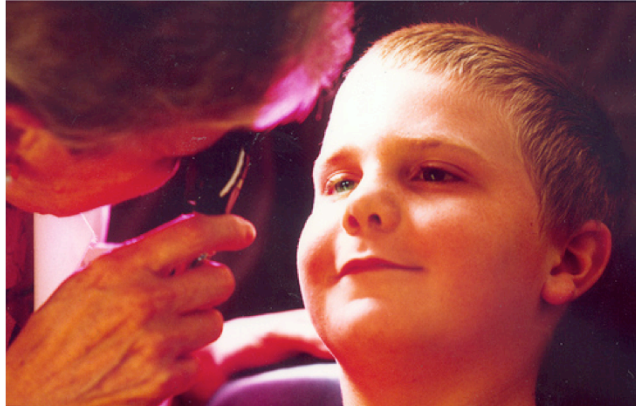You are a third year medical student in your rural Family Medicine rotation. You are asked to go see Oliver, an 18-month-old male presenting to his family doctor's office for his extended well-child visit. Oliver has been well and his parents have no specific concerns on history. You proceed through your physical exam and take out the direct ophthalmoscope to examine Oliver's eyes. As you check for the red reflex you are taken aback. One pupil is red like you would expect, but the other is white. You recognize this finding as leukocoria. What is causing this finding and should you be concerned?

We will come back to the case of Oliver as an example as we go through the podcast.

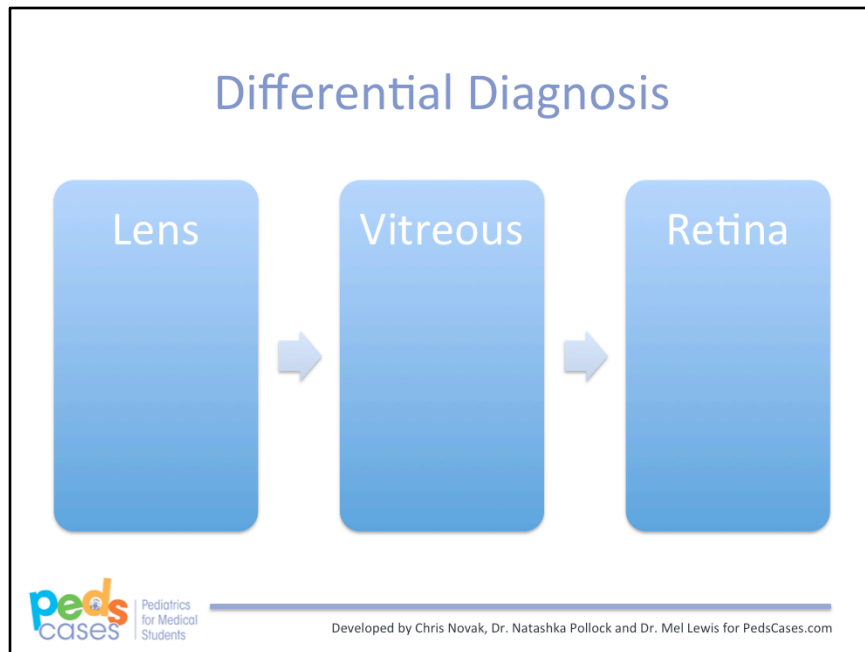


Before we delve into the pathology of leukocoria, let's review the normal physiology and anatomy. The red reflex is a screening physical exam maneuver that uses the direct ophthalmoscope to transmit light through the transparent structures of the eye, to the retina. These structures are important to understand to formulate your differential diagnosis, so let's review them briefly. The retina is the tissue lining the back of the eye where light is focused, and converted to nerve impulses for vision. The retina is a highly vascular structure, so normally when we view it through an ophthalmoscope it appears red. For light to reach the retina it has to pass through a number of transparent structures: the tear film, the cornea, aqueous humour, the lens, and vitreous humour. The cornea is the transparent layer at the front of the eye that covers the iris, pupil and other structures in the anterior chamber. At its periphery, the cornea fuses with the conjunctiva which cover the white sclera which form the shell of the eye. The anterior chamber is the space between the cornea and the lens, which is filled with aqueous humour, a transparent fluid, similar to plasma. The lens is suspended at the back of the anterior chamber, and can change shape in accommodation to focus light on the back of the retina. The rest is of the globe of the eye is filled with a thick gel called vitreous humour. Opacity or distortion of any of these structures can lead to an abnormal red reflex.

Red Reflex




To check the red reflex, take your ophthalmoscope, set the focusing wheel to zero, and set the beam of light to the largest diameter. Stand at arm's length from the child and have them look towards the light source using your voice or a toy. This can be difficult in a neonate. A few tricks are to dim the lights in the room, and to tilt the baby's head backwards. Look closely at the red reflections in both eyes. A normal finding is two red pupils, which are symmetric in character. Abnormal findings are the presence of a white pupil, asymmetry of the reflexes, markedly diminished reflexes, or dark spots on the retina. Diseases which cause leukocoria may be unilateral or bilateral so symmetry does not necessarily rule out pathology. It takes practice to recognize what is normal and what is not, so get plenty of practice while examining healthy patients.



Any abnormal findings on the red reflex suggest opacity of structures in the eye or distortion of light as it passes to the retina. Now let's review the differential diagnosis by going through each of these structures.

First, light passes through the cornea and aqueous humour of the anterior. Lucky for you, there are not really any common disorders of these structure which cause leukocoria. These structures are anterior to the pupil so any distortion of these structures would extend past the margins of pupil and would not cause leukocoria.



Next light hits the lens. The most important diagnosis to consider here is cataracts, the most common cause of leukocoria in children. Cataracts are an opacity of the lens of the eye and while they are typically thought of as a disease of the elderly they can present in neonates and young children. One third of congenital cataracts are genetic with a family history of cataracts, one third are associated with systemic diseases such as Trisomy 21 or metabolic disorders and the other third are idiopathic. In the developing visual system, anything that blocks light from reaching the retina can lead to irreversible vision loss through amblyopia as the neural networks required do not develop appropriately due to deprivation. For this reason, the ideal age to operate is as early as 6-8 weeks.

Cataracts

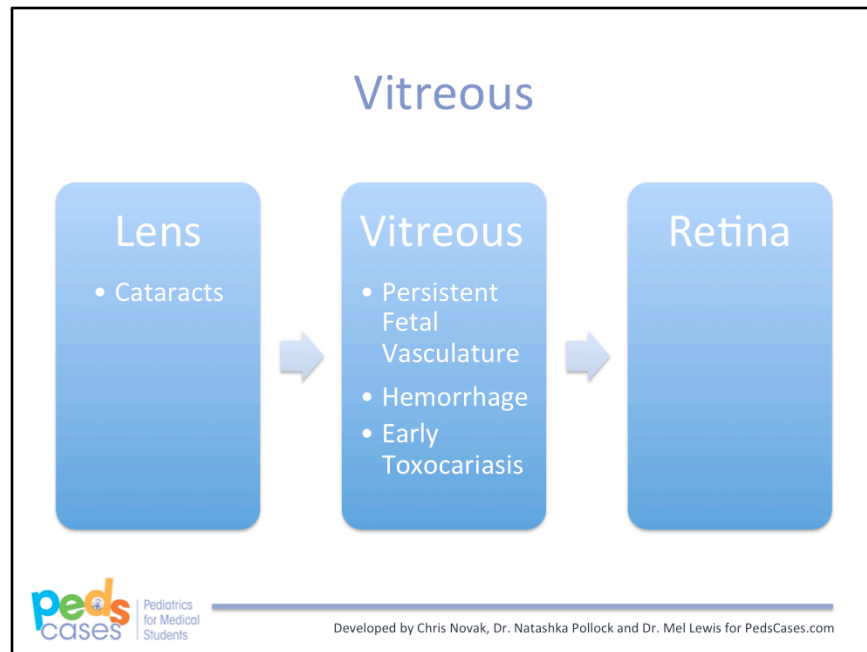
- Opacity of the lens
- Most common cause of leukocoria
- Etiology
 - Genetic (family history)
 - Systemic Illness (Ex. Trisomy 21, Metabolic Disorders)
 - Idiopathic
- Surgery by 6-8 weeks to prevent amblyopia



Pediatrics
for Medical
Students

Developed by Chris Novak, Dr. Natasha Pollock and Dr. Mel Lewis for PedsCases.com

Cataracts are an opacity of the lens of the eye and while they are typically thought of as a disease of the elderly they can present in neonates and young children. One third of congenital cataracts are genetic with a family history of cataracts, one third are associated with systemic diseases such as Trisomy 21 or metabolic disorders and the other third are idiopathic. In the developing visual system, anything that blocks light from reaching the retina can lead to irreversible vision loss through amblyopia as the neural networks required do not develop appropriately due to deprivation. For this reason, the ideal age to operate is as early as 6-8 weeks.



Next we move into the vitreous humour. The first condition we will consider is persistent fetal vasculature. Persistent fetal vasculature is a congenital anomaly where blood vessels in the developing eye fail to regress in development leaving behind a vascular stalk extending through the vitreous from the optic nerve to the lens. Children with this condition tend to present with microphthalmia, or a smaller eye on the affected side, and are at risk of developing glaucoma, cataracts or intraocular hemorrhage.

Any cellular debris from hemorrhage, inflammation or infection in the vitreous can also lead to leukocoria. In vitreous hemorrhage, blood degrades into whitish debris. A vitreous hemorrhage may result from persistent fetal vasculature, trauma, advanced retinopathy of prematurity or a bleeding diathesis such as hemorrhagic disease of the newborn. Infection of the vitreous may cause leukocoria. An example of this is ocular toxocariasis, a thankfully rare systemic infection of roundworms of dogs and cats. Toxocariasis is transmitted to humans when they ingest soil contaminated with dog and cat feces. Children are especially prone to ingesting soil due to hygiene and play habits. Once ingested, the larvae hatch, burrow into the intestinal wall and migrate to various organs of the body. The roundworm larva has a predilection to deposit in the eye, leading to inflammation of the vitreous called endophthalmitis, and eventually

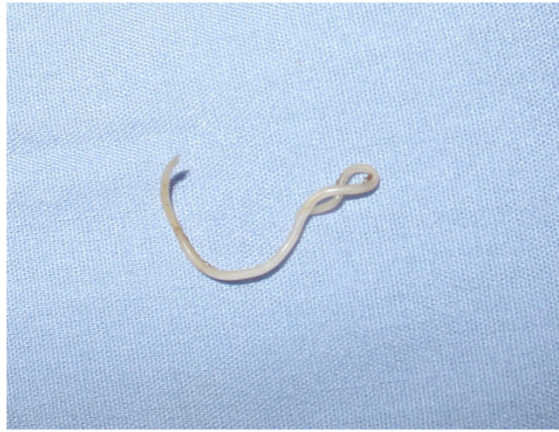Persistent Fetal Vasculature

- Congenital Anomaly
- Blood vessels fail to regress leaving behind stalk from the optic nerve to the lens
- Associated with microphthalmia
- Complications – Glaucoma, cataracts, vitreous hemorrhage

Vitreous Hemorrhage

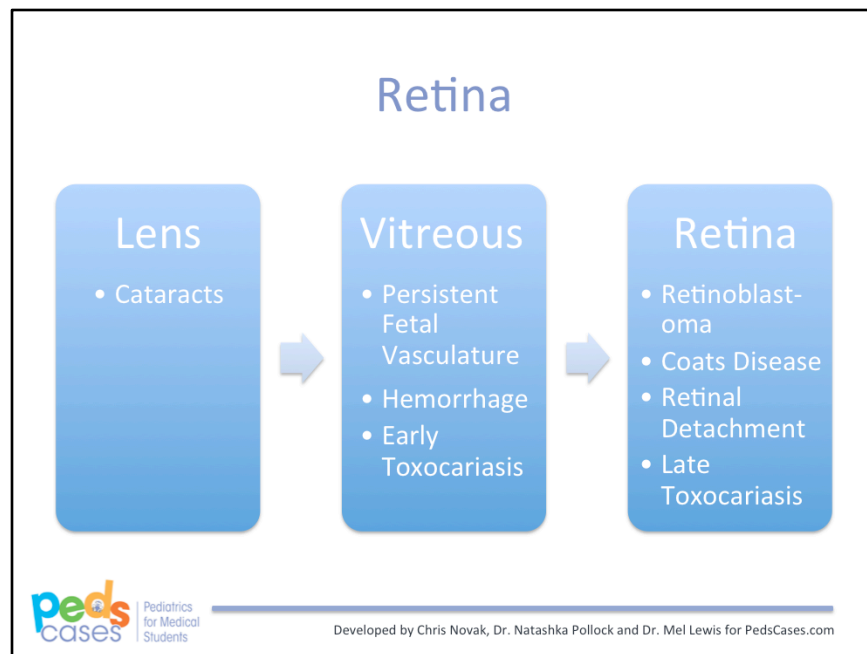
- Blood in vitreous degrades into white debris
- Etiology
 - Persistent Fetal Vasculature
 - Trauma
 - Advanced Retinopathy of Prematurity
 - Bleeding Diathesis (Ex. Hemorrhagic disease of the newborn)

Toxocariasis



Toxocariasis

- Ocular infection of roundworms
- Transmission – Ingesting soil contaminated with dog or cat feces.
- Age of Onset – Average 8-16 years, but can be as young as 2 years
- Early Infection - Endophthalmitis (vitreous)
- Late Infection – Retinal granulomas
- Management – Oral antihelminthics



Moving to the back of the eye we hit the retina. Retinal causes of leukocoria can be divided into conditions that lead to deposition of material below the retina, and those that lead to retinal detachment. Perhaps the most concerning cause of leukocoria is retinoblastoma, an intraocular malignancy which originates from the retina. It most commonly presents in early childhood. The median age at diagnosis is only 18 months with 95% of cases presenting before the age of 5 years. While the majority of cases arise from de novo mutations, up to 10% of children will have a family history of retinoblastoma with a heritable mutation of the RB1 gene. Children with a family history of retinoblastoma should have regular evaluation by an ophthalmologist due to an increased risk of developing malignancy. Leukocoria is the most common presenting finding in retinoblastoma but children may also present with strabismus, nystagmus or a red eye. Without treatment, retinoblastoma is a deadly disease which leads to destruction of the orbit, metastases and death, therefore any child presenting with leukocoria should have an urgent referral to ophthalmology for a dilated ophthalmic examination. Diagnosis is made by clinical assessment. With prompt therapy, retinoblastoma has a greater than 95% five-year survival rate, however children with metastatic disease have only a 50% survival rate at 18 months. Therapy depends on tumour characteristics and prognosis but can include chemotherapy, radiation, cryotherapy, laser therapy and surgical removal of

Retinoblastoma

- Intraocular malignancy originating from retina
- Age of Onset – Median 18 months, 95% before 5 years
- 90% sporadic, 10% family history
- Presentation – Leukocoria, strabismus, nystagmus, red eye
- Prognosis – Early detection 95% five year survival. Metastatic 50% survival at 18 months

Coats Disease

- Exudative retinal vascular disorder, leading to deposition of lipids below retina
- More common in boys
- Age of Onset – Usually 5-9 years
- Leads to vision loss and retinal detachment

Another disease of the retina that can present with leukocoria is Coats disease. Coats disease is an exudative retinal vascular disorder that leads to deposition of lipids below the retina, giving the retina a yellow appearance on exam. Coats is more common in boys and in older children usually presenting between the ages of 5 and 9 years. Eventually Coats disease can lead to retinal detachment.

Retinal Detachment

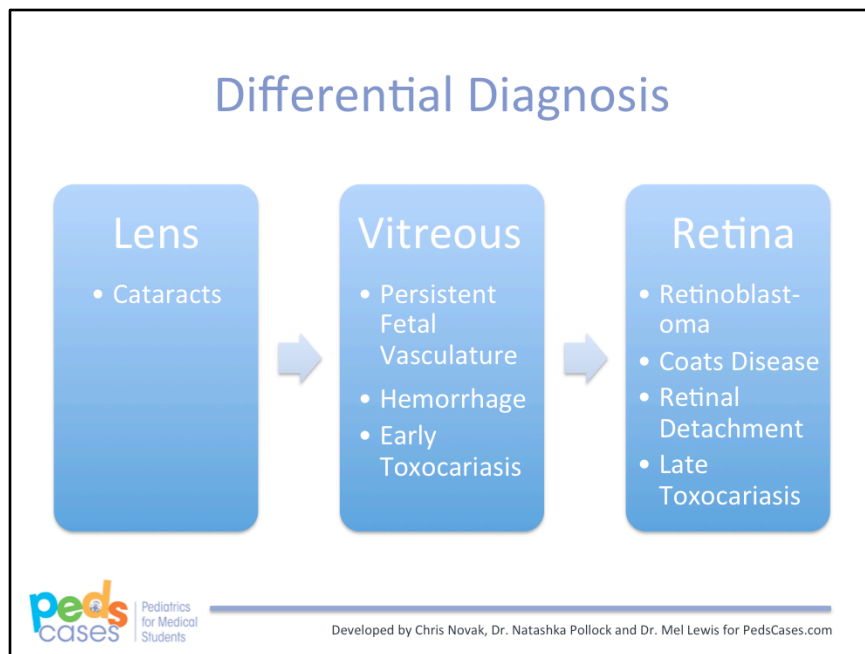
- Red blood vessels removed from back of the eye
- Etiology
 - Trauma
 - Advanced Coats Disease
 - Advanced Retinopathy of Prematurity



Developed by Chris Novak, Dr. Natasha Pollock and Dr. Mel Lewis for PedsCases.com

Any cause of retinal detachment will present with leukocoria, as the red blood vessels associated with the retina are removed from the back of the eye. Causes of retinal detachment include trauma, advanced Coats disease and severe, untreated retinopathy of prematurity.

Finally, there can be significant variation in the pigmentation of the retina in different ethnic groups. For example, the retina in children of Asian and African descent can appear much less red than Caucasian children. An experienced clinician can usually detect this difference, however if you are in doubt you should refer to ophthalmology for a more detailed exam. It is much better to make the mistake of referring a normal child, than it is to risk not referring a child with a vision or life-threatening disease



To review, the causes of leukocoria include lesions of the lens, vitreous and retina. The lens can be affected by congenital cataracts. In the vitreous you can have persistent fetal vasculature, vitreous hemorrhage, or inflammation such as in toxocariasis. On the retina you can have retinoblastoma, Coats disease, or retinal detachment from a variety of causes. Estimates of frequency vary, but the most common cause of leukocoria is generally cataracts, followed by retinoblastoma, persistent fetal vasculature and Coats disease. There are other rare causes of leukocoria, but these are more relevant for specialists.

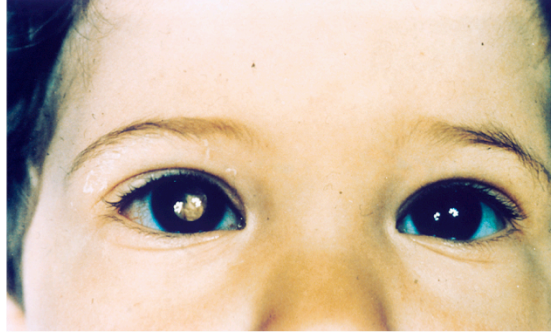
Referral

- All children with leukocoria require URGENT referral to ophthalmology
- Should be seen within one week
- Communicate to parents the urgency of the referral, but advise them of the wide possible differential from severe to benign
- Ophthalmologist will diagnosis with a dilated eye exam

After discovering leukocoria on a physical exam, all children require urgent referral to an ophthalmologist experienced at examining children, and should be seen within one week. You should include in your referral a detailed medical history, including any associated systemic symptoms, any family history of ophthalmic disease, and any other findings on a detailed physical exam. Communicate to the family the urgency of this referral, but advise them of the wide differential from severe to benign causes, and that they will require a specialist to take a closer look. Upon receiving the referral an ophthalmologist can make a diagnosis through a comprehensive ophthalmologic exam and can make the necessary steps to begin treatment for the specific pathology.

Case

Oliver, 18-month-old male. Otherwise well.



Now let's return to our clinical case. You have just noted leukocoria on Oliver's physical exam. After finishing the physical exam, you do a more detailed medical history and find that Oliver has no noted associated symptoms, and has no family history of ophthalmic disease including cataracts or retinoblastoma. You report your findings to your preceptor who confirms the presence of leukocoria. They explain to Oliver's family that one of his pupils appears white on physical exam and that he should be seen quickly by an ophthalmologist in the nearest community. Oliver is diagnosed with early-stage retinoblastoma, devastating news for his family. He is quickly introduced to a pediatric oncology team and begins therapy and goes on to make a complete recovery.

Take Home Points

- 1) Leukocoria can represent serious and treatable disease. Examine the red reflex in all children.
- 2) The most common causes are cataracts, retinoblastoma, persistent fetal vasculature and Coats disease
- 3) All children with leukocoria require an urgent referral to ophthalmology



Developed by Chris Novak, Dr. Natasha Pollock and Dr. Mel Lewis for PedsCases.com

Before we leave, let's finish with a few key take home points:

1. Leukocoria is a rare physical exam finding, but can be a signal of serious and treatable diseases. Therefore, all newborns, infants and children should be screened with examination of the red reflex in routine physical examinations.
2. The most common causes of leukocoria are congenital cataracts, retinoblastoma, persistent fetal vasculature and Coats disease.
3. All children with leukocoria require an urgent referral to ophthalmology for a dilated eye examination.

That concludes our presentation. Thanks for listening to PedsCases podcasts!

Thanks for Listening!

References:

1. American Academy of Pediatrics, Section on Ophthalmology. Red Reflex Examination in Neonates, Infants and Children. Pediatrics. 2009 April; 123(4):1254. Available from: <http://pediatrics.aappublications.org/content/pediatrics/122/6/1401.full.pdf>
2. Kauffman, P. Approach to the child with leukocoria. UpToDate. 2015 Feb 12. Available from: http://www.uptodate.com/contents/approach-to-the-child-with-leukocoria?source=search_result&search=leukocoria&selectedTitle=1~10#H3
3. Kauffman, P. Overview of retinoblastoma. UpToDate. 2015 Feb 17. Available from: http://www.uptodate.com/contents/overview-of-retinoblastoma?source=see_link§ionName=EPIDEMIOLGY&anchor=H2#H20
4. Woodhall, D. Toxocariasis: A review for pediatricians. Journal of the Pediatric Infectious Diseases Society. 2014 Jun; 3(2):154-9.

Image Credits:

1. <https://upload.wikimedia.org/wikipedia/commons/thumb/c/c6/Retinoblastoma.jpg/1280px-Retinoblastoma.jpg>
2. <https://upload.wikimedia.org/wikipedia/commons/thumb/f/f5/Eyesection.svg/2000px-Eyesection.svg.png>
3. <https://www.flickr.com/photos/80030261@N06/7544605754>
4. https://upload.wikimedia.org/wikipedia/commons/5/57/Canine_roundworm_1.JPG



Developed by Chris Novak, Dr. Natasha Pollock and Dr. Mel Lewis for PedsCases.com